Walter Reed Army Medical Center
6900 16th Street, N.W.
Washington, DC 20307

PATIENT INFORMATION:

Patient: WRAMC VC-119M
Patient ID:
Study Date: 11/5/2002
Referring Physician: HWANG INKU

INTRODUCTION:

A 55 year old male presents with:

Screening
Others: 55 y/o male here for enrollment into Virtual Colonoscopy protocol. Patient states doing well w/o change in BM, wt loss, blood in stool. Patient ave risk for colon cancer w/o FH of colonic polyps, colon ca or polyposis syndromes. Patient w/o positive stool guiac test or h/o iron def anemia w/in past 6 months. Patient has had no prior evaluations for colon cancer screening including normal colonoscopies w/in 10 yrs, and normal ACBE w/in past 5 yrs. Patient w/o h/o adenomatous polyps, colorectal cancer, IBD, HNPCC or FAPS. No h/o rectal bleeding, hematochezia, or unintentional wt loss w/in past 12 months. Patient has no contraindications for colonoscopy in general or to fleets prep.

COLON FINDINGS:

(Supine) 6.7 x 5.2 mm round polyp identified in the sigmoid at 21.7 cm from rectum.

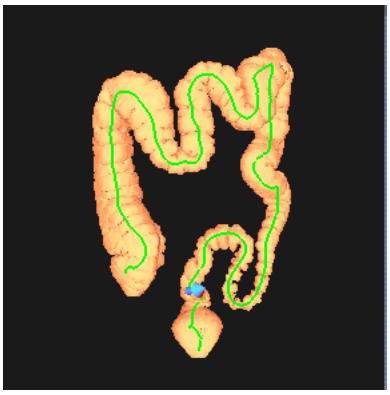

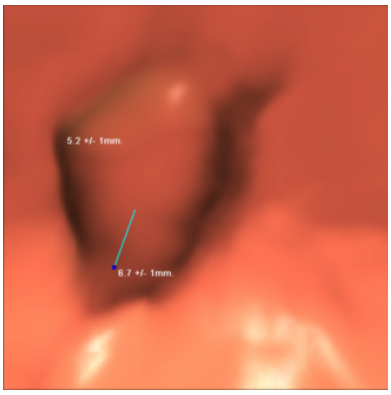

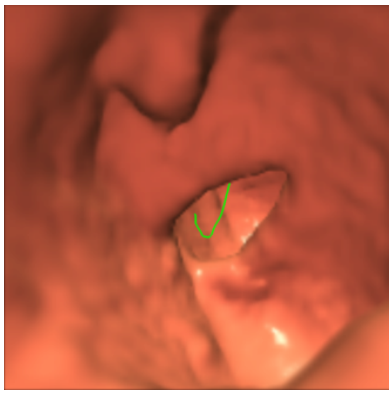


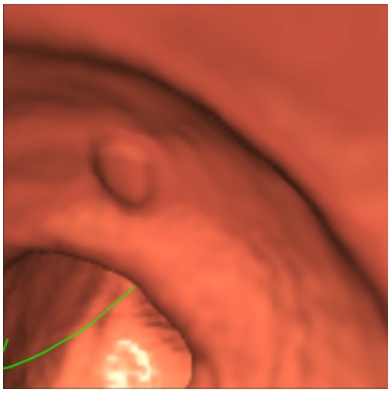
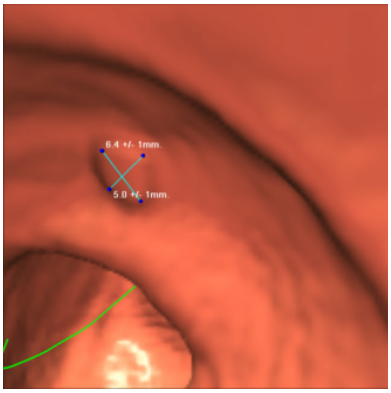

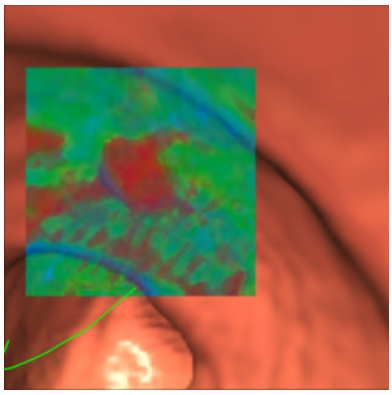

(Supine) Normal finding in the cecum at 170.7 cm from rectum.

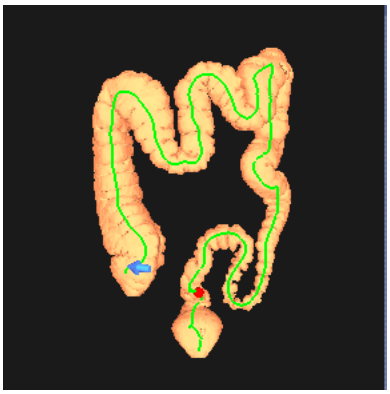
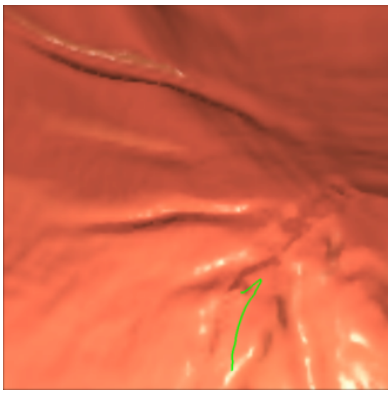
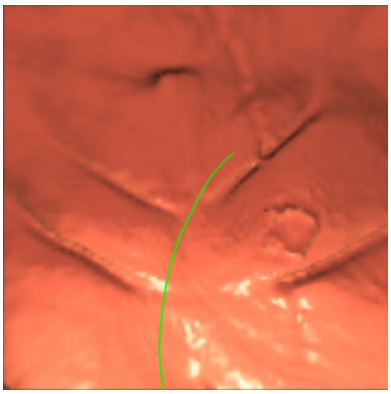

IMPRESSION

- 6mm sessile polyp in sigmoid colon.

J. Richard Choi, ScD, MD