PATIENT INFORMATION:

Patient: WRAMC VC-390M
Patient ID:
Study Date: 5/19/2003
Referring Physician: HWANG INKU

INTRODUCTION:

A 51 year old male presents with:

Screening
Others: 51 yo AAM here for enrollment into Virtual Colonoscopy protocol. Patient states doing well w/o change in BM, wt loss, blood in stool. Patient ave risk for colon cancer w/ FH of colonic polyps, colon ca or polyposis syndromes. Patient w/o positive stool guiac test or h/o iron def anemia w/in past 6 months. Patient has had no prior evaluations for colon cancer screening including normal colonoscopies w/in 10 yrs, and normal ACBE w/in past 5 yrs. Patient w/o h/o adenomatous polyps, colorectal cancer, IBD, HNPCC or FAPS. No h/o rectal bleeding, hematochezia, or unintentional wt loss w/in past 12 months. Patient has no contraindications for colonoscopy in general or to fleets prep.

COLON FINDINGS:

(Supine) Normal finding in the cecum at 140.7 cm from rectum.

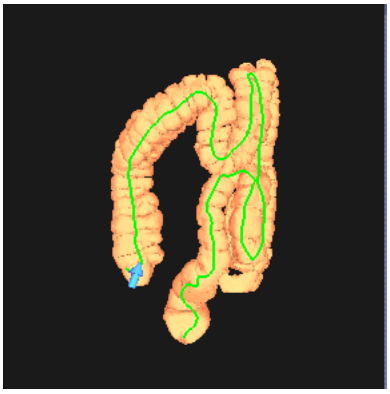

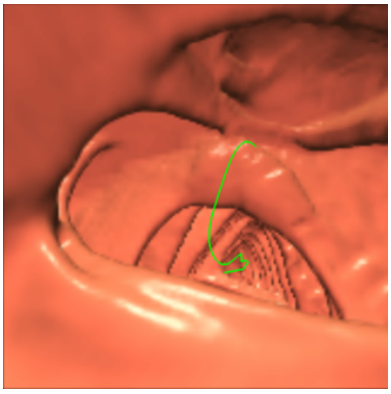

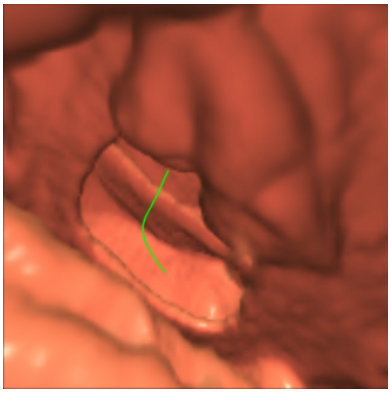

IMPRESSION

- No significant colonic polyp is seen.

J. Richard Choi, ScD, MD